

## Seasonal influenza-related deaths

**Authors:** H. Mushumba<sup>1</sup>; D. Froeb<sup>1</sup>; J. P. Sperhake<sup>1</sup>.

**Affiliations:** <sup>1</sup>Institute of Legal Medicine; University Medical Center Hamburg-Eppendorf; Germany

**Keywords:** Influenza; Autopsy; Immunosuppression; Hamburg

### INTRODUCTION

In this report, we present unusual histological findings from a case of a 42-year old female subject whose general condition rapidly worsened and subsequently succumbed to death following a short course influenza illness. Definitive diagnosis, cause and manner of death were determined following a medico-legal autopsy done at the Institute of Legal Medicine, University Medical Center Hamburg-Eppendorf/Germany. Reporting of this study has been checked and verified in accordance with the CARE (Consensus-based Clinical Case Reporting Guideline Development) checklist.

### CASE REPORT

At the beginning of March, a 42-year-old female subject was reportedly found unresponsive in her apartment located on the outskirts of Hamburg, Germany. As reported by her partner, her general condition had rapidly deteriorated in the early hours of the same morning, which prompted him to call the emergency services for an ambulance.

He further reported that during his telephone conversation with the emergency service personnel, he had clearly indicated that his wife had previously been diagnosed with flu. Furthermore, he reported that between 30-45 minutes prior, she had developed an “extremely swollen blue limb” coupled with “severe shortness of breath”. Upon arrival of the emergency medical services personnel, the patient was found lying unresponsive on the floor. Immediate resuscitation measures were done without success and the patient was pronounced dead on site.

As past medical history, her last family doctor visit had been two days prior to death. The deceased’s partner reported that apart from the diagnosis of flu, this particular visit had been largely uneventful to prompt hospital admission. The patient was known to have Crohn’s disease of which she had been prescribed with regular steroid medication (Budenoside 3mg).

She was not vaccinated against influenza as reported by her family doctor.

Due to the patient’s unclear and rapid worsening of her illness as well as subsequent death, a medico-legal autopsy was requested to determine the cause and manner of death. The body was stored in a 4°C refrigerator pending autopsy, eventually done 6 days post-mortem.

### EXTERNAL EXAMINATION

A body of a middle-aged female, light skin color, body weight 78.5kg and body length 166cm, BMI: 28.5 kg/m<sup>2</sup>

Intense, sparse and permanently fixed blue-violet/reddish lividity on the dorsal side and ventral sides of the body.

Intense and completely formed rigidity still present in the lower limbs.

Sunken eyeballs with gray-greenish colored iris. About 0.4 cm equally dilated pupils, no petechial hemorrhages were noted.

Defibrillator plasters in typical locations noted on the thorax.

A 13-cm vertical midline incision scar as well as a 12-cm horizontal lower abdomen incision scar were noted

No signs of external trauma noted

### AUTOPSY FINDINGS

Approximately 1.0cm skull thickness was measured upon incision. Brain appeared mildly swollen; no rapid glucose test was done due to presence of blood-tinged cerebrospinal fluid. Later analysis of the aqueous humor showed no pathologically elevated glucose levels.

On further exploration of the body cavities following layer by layer incisions, the following were noted: approximately 4.0cm thick abdominal fat, abdominal organs intact and located normally in the peritoneal cavity. The diaphragm on the right side was at the level of the 4<sup>th</sup> rib and between the 4<sup>th</sup> and 5<sup>th</sup> ribs on the left. No pleural effusion was noted on both sides and no lung adhesions to the pleural cavity were remarked.

**Corresponding author:** H. Mushumba; Institute of Legal Medicine; University Medical Center Hamburg-Eppendorf; Germany; Butenfeld 34; 22529 Hamburg; hmushumba@gmail.com; h.mushumba@uke.de; **Potential Conflicts of Interest (Col):** All authors: no potential conflicts of interest disclosed; **Funding:** All authors: no funding was disclosed; **Academic Integrity:** All authors confirm that they have made substantial academic contributions to this manuscript as defined by the ICMJE; **Ethics of human subject participation:** The study was approved by the local Institutional Review Board. Informed consent was sought and gained where applicable; **Originality:** All authors: this manuscript is original has not been published elsewhere; **Type-editor:** insert here

**Review:** This manuscript was peer-reviewed by 3 reviewers in a double-blind review process;

**Received:** 30th Aug 2018; **Original decision:** 10th Oct 2018; **Revised submission:** 12th Oct 2018; **Accepted:** 23rd Oct 2018

**Copyright:** © The Author(s). This is an Open Access article distributed under the terms of the [Creative Commons Attribution License \(CC BY-NC-ND\)](https://creativecommons.org/licenses/by-nc-nd/4.0/) (click here), which permits unrestricted use, distribution, and reproduction in any medium, provided the original work is properly cited. **Publisher:** Rwanda Biomedical Centre (RBC)/Rwanda Health Communication Center, P.O.Box 4586, Kigali

**ISSN:** 2079-097X (print); 2410-8626 (online)

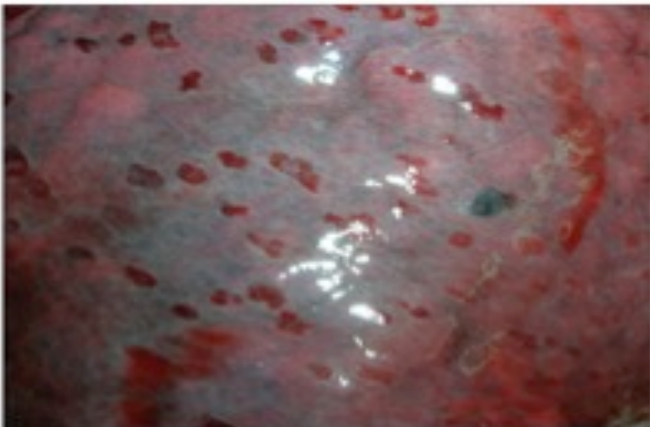
**Citation for this article:** H. Mushumba; D. Froeb; J. P; Sperhake, A Case Report - Seasonal influenza-related deaths”, *Rwanda Medical Journal*. Vol 76, no 2, pp 1-4, 2019

Opening of the pericardial cavity revealed approximately 5ml clear reddish effusion, with further 150ml of coagulated blood collected upon dissection of the great vessels. The ventricles as well as atria appeared of normal size. The endocardium appeared with a dark-red color due to beginning decay. All valves appeared normal. The measured myocardial wall thicknesses were 0.3cm and 1.4cm on the right and left ventricles, respectively. No atrial or ventricular defects were noted. The myocardium appeared homogenous and upon further exploration, no areas of infarction were remarked.

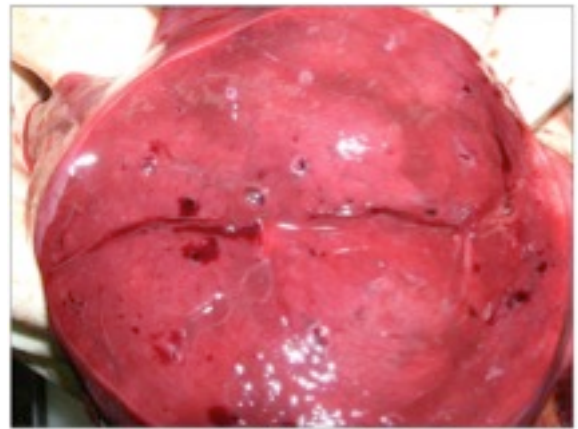
Furthermore, signs of lung inflammation with dark-red discoloration of both lung, massive edema, cloudy appearance of the cutting surfaces in addition to well-demarcated, reddish spots were noted on the lung surfaces. Massive inflammation with a reddish appearance of the tracheal and bronchial mucosae was also noted. The central and peripheral pulmonary vessels were free of emboli. No signs suggestive of poisoning were noted on autopsy.

There was evidence of previous appendectomy as well as ascending colon loop resection with side-to-side anastomoses due to underlying Crohn's diseases. Small bowel mucosal ulceration indicative of Crohn's disease was also remarked. Elsewhere all abdominal organs were of normal size and consistency. All blood vessels appeared normal with no plaque formation and with conserved elasticity.

The measured organ weights were: brain: 1310g; heart: 345g; right lung: 740g; left lung: 480g; right kidney: 125g; left kidney: 135g; liver: 1720g and spleen: 160g



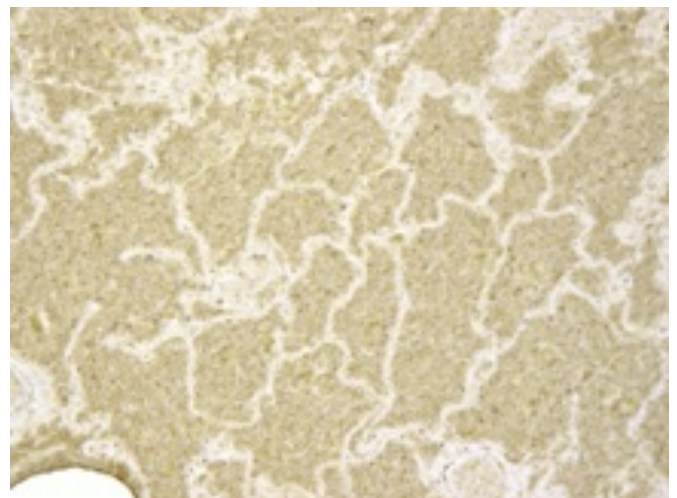
**Fig. 1: Multiple, well-demarcated, reddish spots noted on the lung surfaces before dissection.**



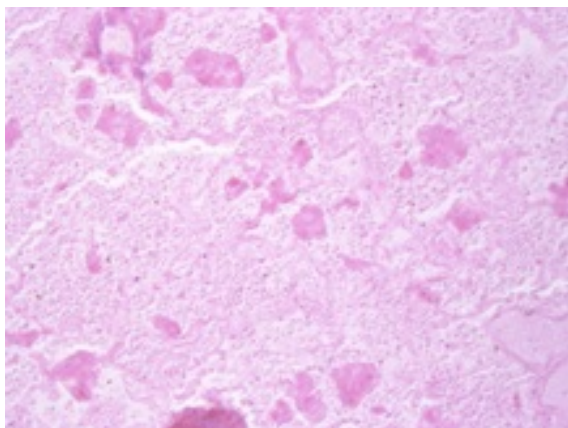
**Fig. 2. Lung inflammation with dark-red discoloration of both lung tissues, massive edema as well as cloudy appearance of the cutting surface seen upon dissection of the lung parenchyma**

Following the autopsy findings, death was presumptively attributed to pneumonia. However the manner of death could not be determined at this point. As a result, tissue samples for histological analysis were collected to further explore the infection as well as to establish the causative agent. Furthermore, tissue samples from the lungs and bronchi as well as lung and tracheal swabs were collected for further virological and bacteriological analysis. Venous blood, urine and stomach content samples were also collected for toxicological analysis.

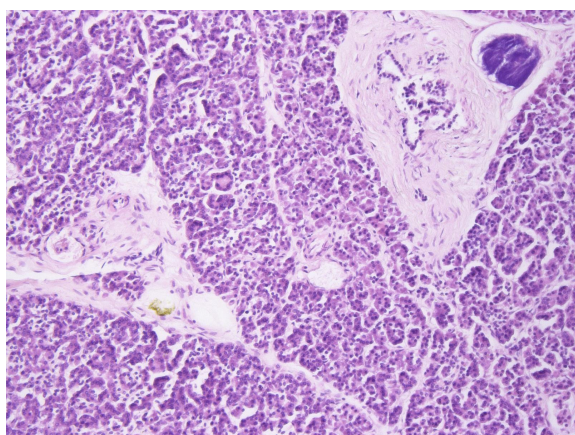
Laboratory results: Influenza B virus was detected in the lung tissues, lung swabs as well as the bronchial tissue samples by RT-PCR. Histologically, there was an ubiquitous dense intra-alveolar infiltrate composed of round cells in the lungs, which, due to severe autolysis were only dimly visible (Fig. 3&4). The amount of autolysis in the lungs was striking in comparison to other organs, which were hardly affected by autolytic changes (as an example, the well-preserved pancreas – an organ typically known for being the first to be destroyed by autolysis (Fig. 5). The micro-morphological correlate of the reddish spots on the pleural surface of the lungs were clusters of erythrocytes.



**Fig. 3. Immunohistochemistry employing antibodies against Myeloperoxidase (MPO), revealed granulocytes as the predominant cell type**



**Fig. 4.** Despite extensive autolysis of the lungs, inflammatory cells could be detected in the alveoli



**Fig. 5:** Well preserved pancreatic tissue without autolytic changes. (H&E staining)

From the microbiology work-up in addition to the histological and autopsy findings, death was conclusively attributed to pneumonia secondary to flu with an eventual *Streptococcus pyogenes* bacterial superinfection.

## DISCUSSION

Influenza is a viral disease of the respiratory tract associated with increased morbidity and mortality if not properly and promptly managed. It is estimated that one-million deaths worldwide are recorded annually (1). Many influenza-related deaths however, are linked to secondary bacterial infections resulting in the role of the primary viral illnesses to go unrecognized (2). Predisposing factors to increased morbidity from influenza-related illnesses include among others non-vaccination status, compromised immune system due to disease, and advanced age (3). Currently, the contribution of influenza to increased morbidity for conditions not previously linked with infection, such as congestive heart failure or ischemic heart disease, has also been recognized (4). Even though influenza illnesses can be prevented by vaccination, reliable data regarding the clinical disease burden and deaths associated with influenza that would potentially serve as a basis for influenza vaccine policy formulation are still lacking. The World Health Organization's Global Agenda on Influenza Surveillance and Control defines priority activities that are crucial to reducing the influenza-related morbidity and mortality

such as supporting coordination of action for influenza control and surveillance, among others (5).

Occurrence of influenza illnesses and related deaths vary greatly between regions and seasons. While influenza illnesses and related deaths in the tropics are recorded evenly throughout the year, peak occurrences in the temperate regions are almost entirely noted in the cold winter months (1). It is estimated that influenza epidemics account for up to 25% of illnesses in the general population in Europe each year (6), while the rate is 5-20% in the US population with approximately 300,000 ensuing influenza related hospital admissions and about 36,000 deaths annually (7). Moreover, the fact that confirmatory virological analyses are not routinely made and the infection-related deaths not indicated on death certificates, makes it even more difficult to clearly estimate the number of deaths attributed to influenza illnesses (8).

Influenza continues to pose a major health burden not only in Europe, but also in other parts of the world. Despite the influenza viruses being relatively simple, RNA-containing viruses with strongly immunogenic surface proteins, their ability to undergo antigenic shift and drift over time enables them to evade the host's immune system which consequently hinders efforts to produce long-lasting vaccines against the disease (9). The composition of the flu vaccine must be reviewed and updated each year to cope with the evolving viruses. Vaccination rates still remain generally very low even with the knowledge that vaccination is the only available preventive measure in all age groups, preventing about 50% of deaths from pneumococcal illnesses and 80% of deaths resulting from influenza-related complications in the elderly (6). Mueller et al. noted in their study that the influenza vaccination coverage rate in Germany only increased minimally from 22.3% in 2002/2003 to 25.1% in 2003/2004 (10). The trend was also more or less similar in other European countries such as Spain, France, UK and Italy for the 2006/2007 season with the highest vaccination rates observed in Germany (27.4%) (11).

Despite the fact that the patient was already taking immune depressing medications (Budenoside) in addition to being in the middle of an influenza epidemic, she had not been vaccinated against influenza. Immunosuppression might explain the rapid deterioration and fatal outcome of the disease in an otherwise healthy 42-year old woman. Even though the reasons for not being vaccinated were not clarified in our case, Mueller et al. noted in their study that the reasons for some people in Germany not being vaccinated included 43.6% who indicated they did not expect to catch influenza; 47.4% were thinking about it but ended up not being vaccinated while 36.6% didn't get the vaccine because the family doctor had not recommended it (10).

The rapid autolysis of the lungs in absence of major autolytic changes in other organs is a novel finding which to our knowledge hasn't been described before. The finding might be an indicator of the aggressive nature of influenza-related pneumonia, leading to extensive cell damage in the affected lungs thus enhancing autolysis post-mortally.

**CONCLUSION:** We highly recommend increased sensitization for influenza vaccination especially to high-risk groups particularly in extremely cold months when an epidemic has been declared. Proper diagnostic workup coupled with prompt and adequate management of flu or flu-like symptoms should also be emphasized.

## REFERENCES

1. Viboud C, Alonso WJ, Simonsen L. Influenza in tropical regions. *PLoS Med.* 2006;3(4):e89. <https://doi.org/10.1371/journal.pmed.0030089>
2. Nicholson KG. Impact of influenza and respiratory syncytial virus on mortality in England and Wales from January 1975 to December 1990. *Epidemiol Infect.* 1996;116(1):51–63. <https://doi.org/10.1017/S0950268800058957>
3. Gran JM, Iversen B, Hungnes O, Aalen OO. Estimating influenza-related excess mortality and reproduction numbers for seasonal influenza in Norway, 1975–2004. *Epidemiol Infect.* 2010;138(11):1559–68. <https://doi.org/10.1017/S0950268810000671>
4. Wong C-M, Chan K-P, Hedley AJ, Peiris JSM. Influenza-associated mortality in Hong Kong. *Clin Infect Dis.* 2004;39(11):1611–7. <https://doi.org/10.1086/425315>
5. Stöhr K. The global agenda on influenza surveillance and control. *Vaccine.* 2003;21(16):1744–8. [https://doi.org/10.1016/S0264-410X\(03\)00065-3](https://doi.org/10.1016/S0264-410X(03)00065-3)
6. Szucs TD, Müller D. Influenza vaccination coverage rates in five European countries—a population-based cross-sectional analysis of two consecutive influenza seasons. *Vaccine.* 2005;23(43):5055–63. <https://doi.org/10.1016/j.vaccine.2005.06.005>
7. Simonsen L, Taylor RJ, Viboud C, Miller MA, Jackson LA. Mortality benefits of influenza vaccination in elderly people: an ongoing controversy. *Lancet Infect Dis.* 2007;7(10):658–66. [https://doi.org/10.1016/S1473-3099\(07\)70236-0](https://doi.org/10.1016/S1473-3099(07)70236-0)
8. Thompson WW, Shay DK, Weintraub E, Brammer L, Cox N, Anderson LJ, et al. Mortality associated with influenza and respiratory syncytial virus in the United States. *Jama.* 2003;289(2):179–86. <https://doi.org/10.1001/jama.289.2.179>
9. Bouvier NM, Palese P. The biology of influenza viruses. *Vaccine.* 2008;26:D49–53. <https://doi.org/10.1016/j.vaccine.2008.07.039>
10. Müller D, Wutzler P, Szucs TD. Influenza Vaccination Coverage Rates in Germany. *Med Klin.* 2005;100(1):6–13. <https://doi.org/10.1007/s00063-005-1113-2>
11. Blank PR, Schwenkglenks M, Szucs TD. Influenza vaccination coverage rates in five European countries during season 2006/07 and trends over six consecutive seasons. *BMC Public Health.* 2008;8(1):272. <https://doi.org/10.1186/1471-2458-8-272>