

Ectopic and Mal-rotated kidney with bilateral hydronephrosis – Case report

Authors: A. Omodan^{1*}; T. Ndayishimye²; E. Muhawenimana²; J. Gashegu¹

Affiliations: ¹Department of Human Anatomy, College of Medicine and Health Sciences, University of Rwanda; ²Department of Surgery, College of Medicine and Health Sciences, University of Rwanda

ABSTRACT

INTRODUCTION: The term ectopic kidney is used to describe a kidney that is found in a place that is not its normal anatomic position while malrotation refers to the abnormal orientation of the kidney. These two are some of the congenital malformations that the kidney is predisposed to in its embryogenesis.

CASE: The current findings were discovered during routine dissections in the Gross lab of the Human Anatomy Department of the University of Rwanda

A left ectopic kidney with a relatively larger than normal size (10.5cm × 5.2cm) was found with the main blood supply arising from the median sacral artery and two other accessory arterial supplies arising from the abdominal aorta. The kidney was mal-rotated, facing laterally, with the ureter on both sides dilated.

CONCLUSION: Knowing kidney variations is ever more important with the rate of increase in renal transplantations and vascular surgeries.

Keywords: Ectopic kidneys, Hydronephrosis, Mal-Rotated Kidney, Unascended Kidney

INTRODUCTION

The embryogenesis of the kidney can be traced to the 4th week of intrauterine life, where it begins as buds in the pelvic region [1]. By the 8th week of life and with continued growth, the kidneys ascend gradually to their normal position, close to the ribs [1]. Located in the lumbar diaphragm fossae, the kidneys are usually known as retroperitoneal organs [2]. The upper pole of the right kidney is located between the intercostal space between the 11th and 12th thoracic vertebrae, while that of the left kidney goes up to the 11th thoracic vertebrae [2]. When the kidneys are not located

in this normal position, it is referred to as being ectopic. It can be located anywhere along the course of its ascent or contra-laterally, referred to as “crossed” [1]. There is evidence of a relationship between vascularization and renal ascent [3]. Amongst the many morphological abnormalities of the kidneys are conditions of rotation which can be seen in normal kidneys as well as ectopic ones [4]. The incidence of ectopic kidney reported in the literature is 1:500 to 1:1100 while the incidence of one normal and one pelvic kidney is 1:800 to 1:3000, Ectopic thoracic kidney is 1:13000, Single pelvic kidney is 1:22000 and crossed renal ectopia 1:7000 [1].

***Corresponding author:** A. Omodan, asking4biola@yahoo.com; **Potential Conflicts of Interest (CoI):** All authors: no potential conflicts of interest disclosed; **Funding:** This study was conducted as a part of the first anatomy annual congress in Rwanda, October 13-15, 2022 sponsored by the MoH, UR, UGHE, AUCA-ASOME, Operation Smile, CHUK and MMI; **Academic Integrity.** All authors confirm that they have made substantial academic contributions to this manuscript as defined by the ICMJE; **Originality:** All authors: this manuscript is original has not been published elsewhere; **Review:** This manuscript was peer-reviewed by two reviewers of the S-CAR committee

Received: 27th November 2022; **Accepted:** 18th February 2023.

Copyright: © The Author(s). This is an Open Access article distributed under the terms of the Creative Commons Attribution License (CC BY-NC-ND) ([click here](#)) which permits unrestricted use, distribution, and reproduction in any medium, provided the original work is properly cited. **Publisher:** Rwanda Biomedical Centre (RBC)/Rwanda Health Communication Center, P. O. Box 4586, Kigali. ISSN: 2079-097X (print); 2410-8626 (online)

Citation for this article: A. Omodan; T. Ndayishimye; E. Muhawenimana et al. Ectopic and Mal-rotated kidney with bilateral hydronephrosis – Case report. Rwanda Medical Journal, Vol. 80, no. 1, p. 76-78, 2023. <https://dx.doi.org/10.4314/rmj.v80i1.9>

CASE PRESENTATION

The case was discovered during a routine dissection of a 47-year-old male cadaver in the Department of Human Anatomy of the University of Rwanda.

On reaching the posterior abdominal wall, we identified a Median sacral artery that perfused the lower pole of a left ectopic kidney. The right kidney was in a normal position, but the left kidney was bigger than normal (10.5cm × 5.2cm), located in a lumbar position, slightly supero-lateral to the aortic bifurcation and was mal-rotated into type E rotation (Facing laterally) (Figure 1).

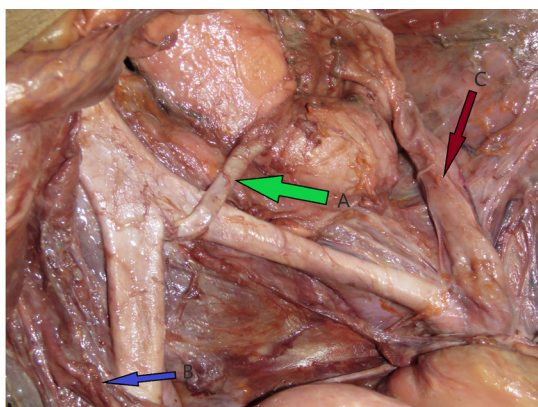


Figure 1: The median sacral artery

A crosses the common iliac artery to supply the left kidney. It makes an impression on the kidney as it goes to enter the laterally facing hilum. *B* shows the right dilated ureter in its course over the right common iliac artery. *C* shows the dilated left ureter in its course to the bladder

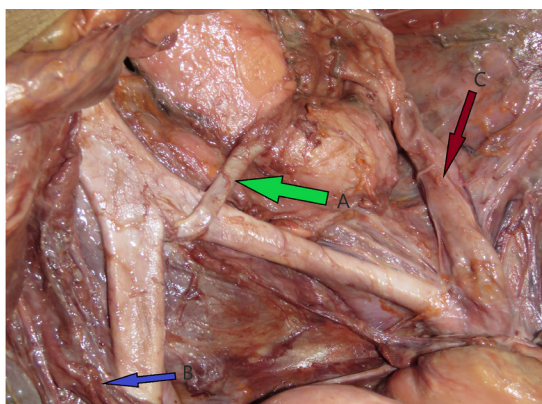


Figure 1: The anterior branch of the accessory blood supply to the kidney from the aorta

A it courses along the upper pole on its way to the hilum. *B* shows the posterior division of the accessory arterial supply as it goes posteriorly to pierce the left kidney in its supply.

The Median sacral artery coursed laterally to run anterior to the left common iliac and the supplied kidney and reached the renal hilum, which was laterally positioned (Figure 1). Through this course, it compressed the kidney, making an impression on the junction of the lower and middle aspects of the kidney. The left kidney has an accessory arterial branch from the abdominal aorta at approximately L1-L2 and supplies a portion of the upper moiety (Figure 2). This upper artery is subdivided into an anterior branch which courses above the upper pole to reach the hilum without making an impression on the kidney. The posterior branch did not follow the course of the anterior division but instead entered posteriorly, and both branches surrounded the upper moiety (Figure 2). The left renal vein drained into the inferior vena cava and received the gonadal, lumbar, phrenic, and adrenal tributaries. The dilated left ureter (Figure 1) runs lateral to the kidney, then anterior to its lower pole to cross the iliac vessels, enter the pelvis, and insert in the bladder in an approximately normal position. The right kidney was normal in size and had one artery and one vein originating from normal locations; however, the ureter was dilated and taking the normal course (Figure 1).

DISCUSSION

The literature has two forms of embryogenesis for the kidney [5]. The first alludes to the fact that the kidneys begin as pelvic rudiments, which have to undergo ascension and rotation induced by substances secreted by the growing kidney before it gets to the normal position. The second proffer that the ascension is actually due to the fast growth of the fetal caudal extremities [5]. There are quite a number of factors that may interfere with this renal embryogenesis [6]. One of the outcomes of this intervention will be renal ectopia which may be found in the pelvis and abdomen or rarely in the thorax and may be unilateral or bilateral [7,8]. Generally, the ectopic kidney is more likely to be smaller in size, with an irregular shape, and also of varying rotation with blood supply from many arteries arising from different levels [5].

The kidney found in our case was bigger than the normal kidney, and it had an irregular shape with a number of arterial supplies. The pattern of its arterial supply may indicate the time of embryogenesis when the interference began to

occur [9]. We know that while the kidney, early on in development, gets its blood supply from the branches of the external and internal iliac arteries, it begins to get supplied from direct branches from the abdominal aorta by the eighth week [10]. These different arterial supplies do not ascend with it to their final position, but they regress, and their final supply is provided higher up in the lumbar region [9]. Our kidney is supplied majorly by the median sacral artery, which enters the hilum, while another branch from the abdominal aorta supplies the upper pole of the kidney. Anomalies of Rotation may be seen in normal or ectopic kidneys. Four rotational anomalies have been identified. Non-Rotation-Renal pelvis facing ventrally, Incomplete Rotation-Ventromedially, Reverse, and Excessive Rotation-Hilum faces laterally [1]. In our case, it is the excessive rotation-hilum faces laterally. Our cadaver had bilateral hydronephrosis. Although the cause could not be readily identified, it is known that the ectopic kidney is more prone to hydronephrosis and kidney stones [5].

Ectopic kidneys have a lot of clinical significance due to their abnormal positioning, malrotation, and varying arterial supply. Also, the positioning of ectopic kidneys makes them vulnerable to trauma [5]. This congenital anomaly may remain undetected if it is asymptomatic, only to be discovered accidentally during some other routine investigations [5]. With the increase in the rate of renal transplants and vascular surgeries, knowledge of these various types becomes imperative [5].

REFERENCES

1. Suresh, S. Malrotated Ectopic Kidney – A Case Report and Review of Literature. SASJS 2020, 6,

268–272, doi:10.36347/sasjs.2020.v06i07.002.

2. Cunningham, D.J.; Romanes, G.J. *Cunningham's Manual of Practical Anatomy*; Oxford medical publications; 15th ed.; Oxford University Press: Oxford ; New York, 1986; ISBN 978-0-19-263138-1.

3. Das, S.; Amar, A.D. Ureteropelvic Junction Obstruction with Associated Renal Anomalies. *Journal of Urology* 1984, 131, 872–874, doi:10.1016/S0022-5347(17)50689-8.

4. Ingole, I.V.; Ghosh, S.K. Laterally Rotated Kidney - A Rare Congenital Anomaly. *Journal of the Anatomical Society of India* 54, 2005, doi:https://www.indmedica.com/journals.php?journalid=8&is sueid=61&articleid=750&action=article.

5. Zăhoi, D.E.; Miclăuș, G.; Alexa, A.; Sztika, D.; Pusztai, A.M.; Farca Ureche, M. Ectopic Kidney with Malrotation and Bilateral Multiple Arteries Diagnosed Using CT Angiography. *Rom J Morphol Embryol* 2010, 51, 589–592.

6. Gülsün, M.; Balkanci, F.; Çekirge, S.; Deger, A. Pelvic Kidney with an Unusual Blood Supply Angiographic Findings. *Surg Radiol Anat* 2000, 22, 59–61, doi:10.1007/s00276-000-0059-6.

7. Zornow, D.H. Embryology of Urinary Incontinence. *Urology* 1977, 10, 293–300, doi:10.1016/0090-4295(77)90153-4.

8. Dretler, S.P.; Olsson, C.; Pfister, R.C. The Anatomic, Radiologic and Clinical Characteristics of the Pelvic Kidney: An Analysis of 86 Cases. *Journal of Urology* 1971, 105, 623–627, doi:10.1016/S0022-5347(17)61591-X.

9. Moore, K.L.; Persaud, T.V.N.; Torchia, M.G. *The Developing Human: Clinically Oriented Embryology*; 8th ed.; Saunders/Elsevier: Philadelphia, PA, 2008; ISBN 978-1-4160-3706-4.

10. Asghar, M.; Wazir, F. Prevalence of Renal Ectopia by Diagnostic Imaging. *Gomal Journal of Medical Sciences* 2004, 6,